

Vascular Skills Lab Two

I. OBJECTIVES

By the end of this laboratory session participants should be able to . . .

- 1) Demonstrate proper use of vascular instruments
- 2) Dissect and gain distal and proximal control of the aorta
- 3) Demonstrate Peracute technique of end to side vascular anastomosis

II. ASSUMPTIONS

The resident has reviewed vascular anastomosis technique and anatomy. The resident has practiced the art of sewing vascular anastomosis using the graft and suture material provided to them.

III. SUGGESTED READING

Chapters 192 in Mastery of Surgery, 5th edition. Editor, Fischer, J. Lippincott William & Wilkins. Philadelphia 2007.

IV. ANATOMICAL CONSIDERATION

Although the approach to the human aorta is through the peritoneum centrally with the small bowel on the right, in the swine model, the best approach is by mobilizing the intestines to the left. This is best accomplished by incising the right flank attachments of the small and large intestines. The entire bowel is then mobilized to the left, exposing the aorta quite nicely. There are usually one to two spinal arteries off of the posterior of the aorta. One should be cognizant of this when trying to obtain distal and proximal control.

V. DESCRIPTION OF LABORATORY MODULE

Two pigs will be set up for two to three residents per pig. Residents are to dissect out the aorta, obtain distal and proximal control, and make longitudinal arteriotomy. An end to side vascular anastomosis with dacron or gortex graft will then be performed.

VI. DESCRIPTION OF TECHNIQUE/PROCEDURE

Vessel handling

Blood vessels are far less forgiving than other tissues commonly handled in general surgical practice. The vessel wall is made up of three layers, all of which are delicate and easy to traumatise. This is even more the case when the vessel is diseased. As a rule, the vessel wall should never be grasped between forceps. During dissection, the surgeon should endeavour to 'dissect the vessel off the patient'. If touching the vessel is truly unavoidable, only grasp the adventitia and, even then, only lightly. Often the closed forceps

can be used to deflect the vessel or traction on a suture or neighbouring structure can afford the exposure required.

After circumferential vessel dissection, to obtain control of the vessel, slings are carefully placed. This should be done using a right-angled forcep, but resist the temptation to push the instrument through remaining tissue on the invisible surface of the vessel. The tangible resistance is often due to the presence of a significant branch artery or venous tributary and it is all too easy to avulse these by the clumsy use of the right-angled forceps. When this situation arises, patiently return to scissor dissection until all intervening tissue is cleared. Traditionally, right-angled forceps are passed around arteries in a direction away from the neighbouring vein to minimise the risk of venous trauma.

Vascular clamps are potentially dangerous. They should be applied with care and only as tight as is necessary to arrest blood flow. Try to place clamps to aid the subsequent procedure rather than hinder it. Select a clamp of appropriate size and strength for the vessel being treated.

Vascular sutures and needles

Vascular sutures are non-absorbable and monofilament. They pass smoothly through the vessel wall causing minimal disruption to the component layers. The size of suture used will depend largely on the size of vessel in question and the extent of disease. Generally speaking, 2/0 and 3/0 sutures are used for the aorta, 3/0 and 4/0 for the iliac arteries, 5/0 and 6/0 for the femoral and popliteal arteries and 7/0 for the crural and brachial arteries. For the direct suture of veins, size again relates to vessel calibre, although often, relatively smaller sutures will be used due to the relatively thin venous wall.

The needles used in vascular surgery are curved but not semi-circular. This configuration ensures that when they are used correctly and enter the vessel wall perpendicular to its longitudinal and transverse axes, the smallest needle hole is created. Often, so-called 'calcium cutting' or specially-strengthened needles are needed to traverse calcified arterial wall.

Suture technique

The needle should be mounted on the needle-holder approximately one-third to half-way along its length from the point. Try to create an 'open' angle between the needle and holder. This approach allows for the maximum possible manoeuvrability for the operator. As a rule, sutures should be passed from within the vessel lumen outwards. This guarantees that the intima is tacked down and cannot be raised as a flap after blood flow is restored. This latter event is disastrous as vessel occlusion and thrombosis can occur. The object of all vascular suture lines is to create an everted anastomosis with even tension that is completely haemostatic. In order to minimise damage to the vessel wall during suturing and to guarantee precise suture placement, it is recommended that the suture is passed through the vessel wall by a number of short pushes of the needle. Do not grasp the needle by its point after it has passed through the vessel, as this will blunt it and compromise the safe performance of the remainder of the anastomosis. Avoid ripping the needle through the vessel wall as this leads to the creation of slits instead of needle holes. These will inevitably leak and cause you problems.

When tying knots with vascular sutures, it is important to have all vessels clamped to avoid the knot being tied loose. A useful tip for snugging down the first throw is to tie a double throw or to tie the first two throws as a 'granny knot' followed by carefully squared reef knots. Six to eight throws in total should ensure against knot slippage.

Arteriotomy

After obtaining exposure and control of the artery, the next stage in all procedures is opening the vessel. The length of the arteriotomy and whether it is performed transversely or longitudinally depends principally on which procedure is being carried out. If an embolectomy is being performed, a transverse arteriotomy usually suffices and can be closed primarily. However, if it is anticipated that an endarterectomy or graft anastomosis will be necessary, a longitudinal arteriotomy is used. Except where the artery is very large, it is not possible to close such an arteriotomy primarily and a patch will be required. The danger with primary closure of a longitudinal arteriotomy is the creation of a significant stenosis with all the expected haemodynamic consequences.

Technique

- Most surgeons use either a number 11 or 15 blade. The vessel should be steadied (but not grasped) so that it is stabilised whilst the arteriotomy is being fashioned. Make the incision in the centre of the surface of the artery facing you.
- With the blade pointing away from you, a short stabbing technique should be used. Sudden movements and excess pressure can lead to the posterior wall of the vessel being either traumatised or incised. In the real-life situation, remember that the opposite wall of the artery may be diseased and, therefore, more vulnerable to this kind of inadvertent injury.
- On entering the lumen proper a 'flash' of blood will be seen. At this point use Potts' angled scissors to complete the arteriotomy. The lower blade of the scissors should be placed in the lumen of the artery with care. By lifting this blade towards you, damage to the opposite side of the vessel will be avoided. Then, cut the desired length of arteriotomy with even cuts (Figure 1.1).
- In general, the length of arteriotomy will be two to three times the diameter of the vessel. Clearly, if a very long endarterectomy or other similar intervention has been performed, a longer incision will be needed. For this exercise open the model artery for 3 cm and excise a small ellipse of the 'vessel' wall.

Where bi-directional flow is required at a vascular anastomosis, the technique employed is the end-side anastomosis. As with all of the exercises on this course, there are several different ways of completing an end-side anastomosis. The so-called 'parachuted' technique described below allows the accurate placement of every suture and, thereby, guarantees that the edges of the graft and artery are everted precisely.

Technique

- An arteriotomy is fashioned which is two to three times the length of the vessel. (In the model provided, it helps to excise an ellipse of the 'artery'). You will be provided with a length of a poly- tetrafluoroethylene (PTFE) graft, which is one of the commonly used prosthetic bypass graft materials in clinical practice.
- Cut the graft as shown in a 'lazy S' configuration. This guarantees that the graft end of the anastomosis will be oval shaped. If the graft is cut straight across, the apices of the oval are pointed and this could lead to stenosis at the heel and toe of the anastomosis (Figure 4.1)

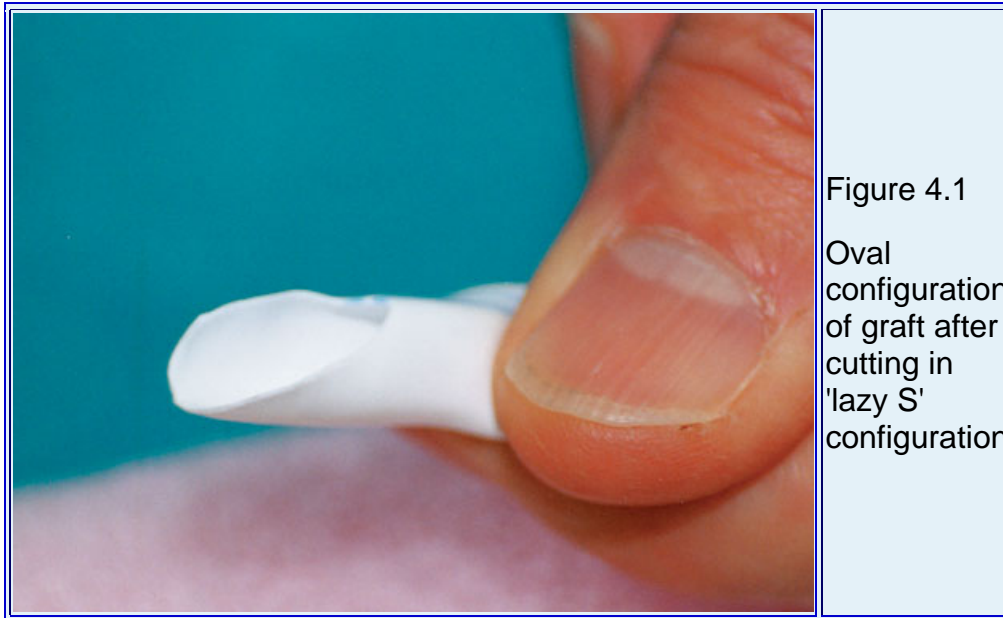

Figure 4.1
Oval configuration of graft after cutting in 'lazy S' configuration

-
- Place the graft opposite the anastomosis so that the correct orientation is maintained. Holding the toe of the graft with a 'mosquito' forceps is helpful. Commence suturing on the far side of the arteriotomy about three suture bites from the heel. Place the sutures from outside to in on the graft and vice versa on the artery. Maintain even tension on the lengths of suture between the graft and artery so that you do not tangle the suture. Your assistant should keep even tension on the suture as you hand it to them between bites (Figure 4.2).

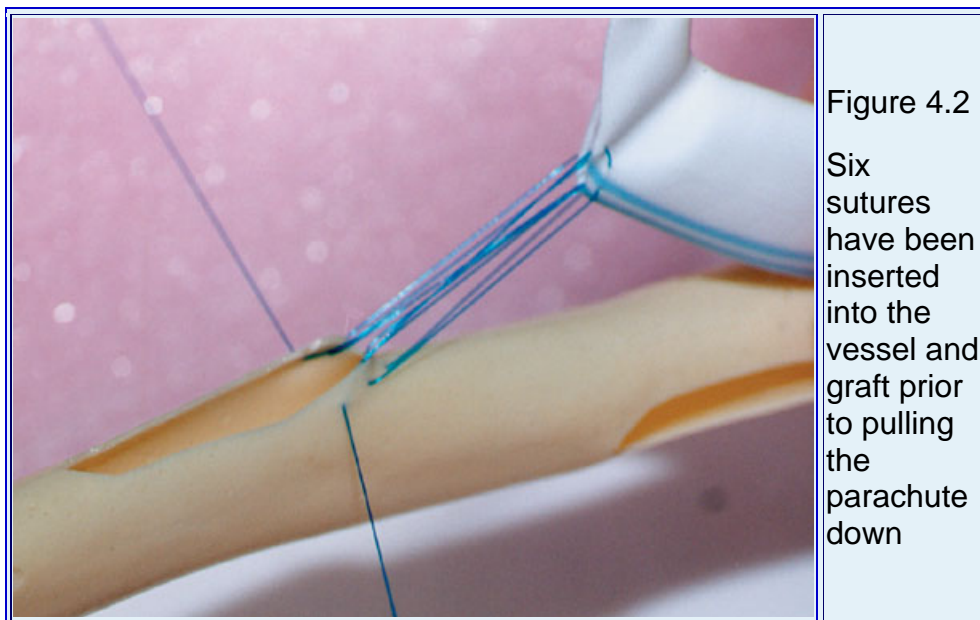


Figure 4.2
Six sutures have been inserted into the vessel and graft prior to pulling the parachute down

-
- Once you have worked around the heel (a total of six to eight bites), you are ready to pull the parachute down. The assistant should maintain even tension on the forceps attached to the toe of the graft, the operator controlling the two ends of suture. Snug the graft down gently by applying even downward force. Make sure that you do not lift the suture up from the vessel wall as it can cut out and damage the artery.

- If the suture becomes looped, lift up on the toe of the graft until all of the unevenly long loops have pulled straight and then repeat the process of traction on the sutures. Usually, this process is repeated three times or so until the graft is snugged down. Before continuing the suturing, check that there are no loose loops around the heel. They should be sorted out now rather than after the anastomosis is completed.
- Using the suture on the 'far' side of the anastomosis, continue suturing towards the toe of the graft. At the toe, in order to avoid stenosis, make sure that you take an adequate number of bites (Figure 4.3). It is helpful to think of the toe of the anastomosis as a clock face and that each suture represents one hour mark.




Figure 4.3
Working
around the
'toe' of the
anastomosis

-
- Continue down the 'near' side to about half way. Shod this suture as before, and, using the other end, suture away from the heel, finishing next to the other end of suture. Remember care should be taken to flush the anastomosis before tying the suture down. Some surgeons tie 'across' the suture line by making sure that one needle exits on the graft side and the other on the artery side. This is really only necessary if there is insufficient graft or artery between the two sutures to avoid the suture cutting through when tied down (Figure 4.4).



-
- Make sure to excise your anastomosis and inspect it from the inside. Are all the edges everted?

*borrowed from the Royal College of Surgeons of Edinburgh Surgical knowledge and skills web site. <http://www.edu.rcsed.ac.uk/index.htm>

VII. EQUIPMENT NEEDED

- 1) 5mm dacron or gortex grafts of 15cm length x6
- 2) 5-0 prolene on vascular needle (RB-1 or RB-2)
- 3) Satinsky vascular clamps
- 4) Bulldog Vascular clamps
- 5) Castro-viejo needle drivers x2
- 6) Right angle clamps
- 7) Debakey forceps
- 8) Metzenbaum scissors x2
- 9) Potts scissors x2
- 10) Suction
- 11) weitlaner retractors
- 12) Gloves

VIII. REFERENCES

Chapters 192 in Mastery of Surgery, 5th edition. Editor, Fischer, J. Lippincott William & Wilkins. Philadelphia 2007

The Royal College of Surgeons of Edinburgh Surgical Knowledge and Skills Web Site. <http://www.edu.rcsed.ac.uk/index.htm>

